

PATIENT

Cassidy Boyer

PRESENTING CLINICAL SIGNS

Patient presents for a grade 4/6 heart murmur. Current meds: Heartgard and Frontline.

SPECIES

Canine

BREED

Collie Mix

SEX

Female Spayed

AGE

12 years

WEIGHT

60 lbs

ULTRASONOGRAPHIC EXAMINATION OF THE HEART

CANINE CARDIAC PARAMETERS	MR VMAX (m/s)	TR VMAX (m/s)	LA/AO (Boon method)	LA/AO (Heart Base; Swe)	FS (%)	EF (%)	EPSS (cm)
NORMAL PARAMETER	4.5-5.5	<2.7	1.3	<1.6	28-40	40-100	<0.6
PATIENT	6.0	N/A	1.1	1.3	30	57	0.27
CANINE CARDIAC PARAMETERS	HR (BPM)	AV VMAX (m/s)	PV MAX (m/s)	BODY WEIGHT (kg)	LA 2D short axis Base view (cm)	LVIDd Avg; 2D and m-mode short axis (cm)	LVIDs Avg; 2D and m-mode short axis (cm)
NORMAL PARAMETER	50-100	0.7-1.7	0.7-1.6	BELOW	BELOW	BELOW	BELOW
PATIENT	NM	1.4	1.1	27.2	2.43	4.3	3.0

Cardiac Presentation

The **left atrium** is of normal size with no evidence of smoke or thrombus formation. The **left ventricle** is normal in diameter with normal wall thickness and demonstrates good systolic function. The **right atrium** is subjectively of normal size and **right ventricle** dimensions and systolic function are subjectively normal. There is mild to moderate **mitral valve** regurgitation and trivial **tricuspid valve** regurgitation noted, with irregular thickening of the mitral valve leaflets. There was no evidence of chordae tendineae rupture or valvular prolapse in either valve and no vegetative lesions were seen. The **aortic** and **pulmonary valves** both exhibit normal appearance and function. The **main pulmonary artery** appears normal. There is no evidence of pulmonary hypertension. No pericardial/pleural effusion or cardiac masses are seen. There is no evidence of an arrhythmia.

ULTRASONOGRAPHIC FINDINGS

Myxomatous mitral valve disease – Stage B1.

INTERPRETATION OF THE FINDINGS & FURTHER RECOMMENDATIONS

- No medication is warranted at this time.
- Daily monitoring of the sleeping respiratory rate at home is recommended, and if the sleeping respiratory exceeds 35 breaths per minute, then a prompt recheck physical examination and chest radiographs to assess for pulmonary edema would be warranted.
- The patient may benefit from a cardiac diet such as Purina's "CardioCare" veterinary diet.
- Recheck echocardiogram is recommended in 6-8 months. MMVD is a progressive disease, and while no medication is warranted now, it may be beneficial in the future.
- If anesthesia is needed, the following recommendations are suggested:
 - Avoid α -2 agonists such as dexmedetomidine and xylazine.

INTERPRETED BY

Tam Mengine, DVM,
DABVP (canine/feline
practice)

IMAGING PERFORMED BY

Kelly Vazquez

HOSPITAL NAME

Sova Animal Hospital

REFERRING VET

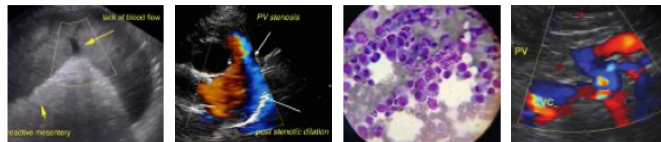
Dr. Ammeraal

INVOICE

12451

DATE

3.17.23



PATIENT

Cassidy Boyer

SPECIES

Canine

BREED

Collie Mix

SEX

Female Spayed

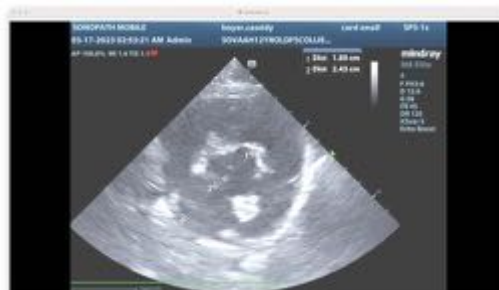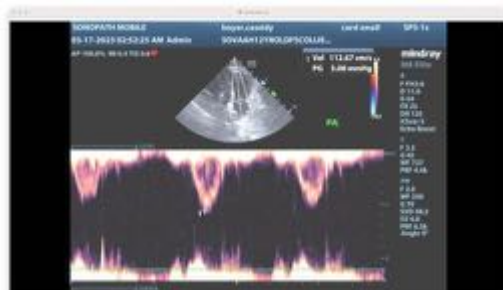
- Pre-medication with an opiate and a benzodiazepine is recommended. Additionally, Gabapentin 10mg/kg PO and trazodone 5mg/kg PO given first thing in the morning on the day of the procedure can further reduce inhalant anesthetic requirements.
- Pre-oxygenation, followed by induction with propofol or alfaxalone is recommended, followed by maintenance with isoflurane or sevoflurane.
- When feasible, the use of local anesthetic blocks can decrease maintenance anesthetic requirements.
- Moderate use of IV fluids throughout the procedure is recommended, with a starting dose of 3-5ml/kg/hr, with modest increases as needed to support blood pressure, but not to exceed a total volume of 20-30ml/kg for the procedure. The minimum volume necessary to maintain adequate blood pressure is desirable.
- Use atropine, if necessary, to maintain a HR > 90 throughout the procedure. If available, a dopamine or dobutamine CRI can be used for additional blood pressure support if the patient experiences hypotension.

AGE

12 years

WEIGHT

60 lbs

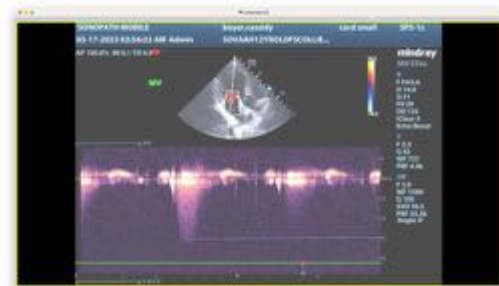
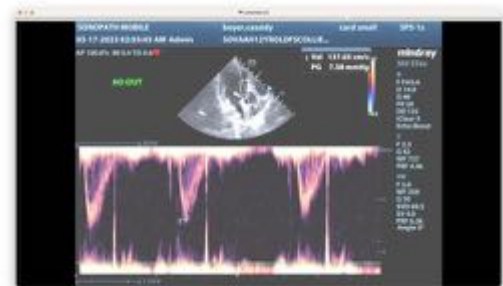


INTERPRETED BY

Tam Mengine, DVM,
DABVP (canine/feline
practice)

IMAGING PERFORMED BY

Kelly Vazquez



HOSPITAL NAME

Sova Animal Hospital

REFERRING VET

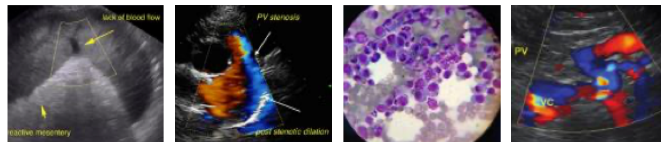
Dr. Ammeraal

INVOICE

12451

DATE

3.17.23



PATIENT

Cassidy Boyer

SPECIES

Canine

BREED

Collie Mix

SEX

Female Spayed

AGE

12 years

WEIGHT

60 lbs

INTERPRETED BY

Tam Mengine, DVM,
DABVP (canine/feline
practice)

**IMAGING
PERFORMED BY**

Kelly Vazquez

HOSPITAL NAME

Sova Animal Hospital

REFERRING VET

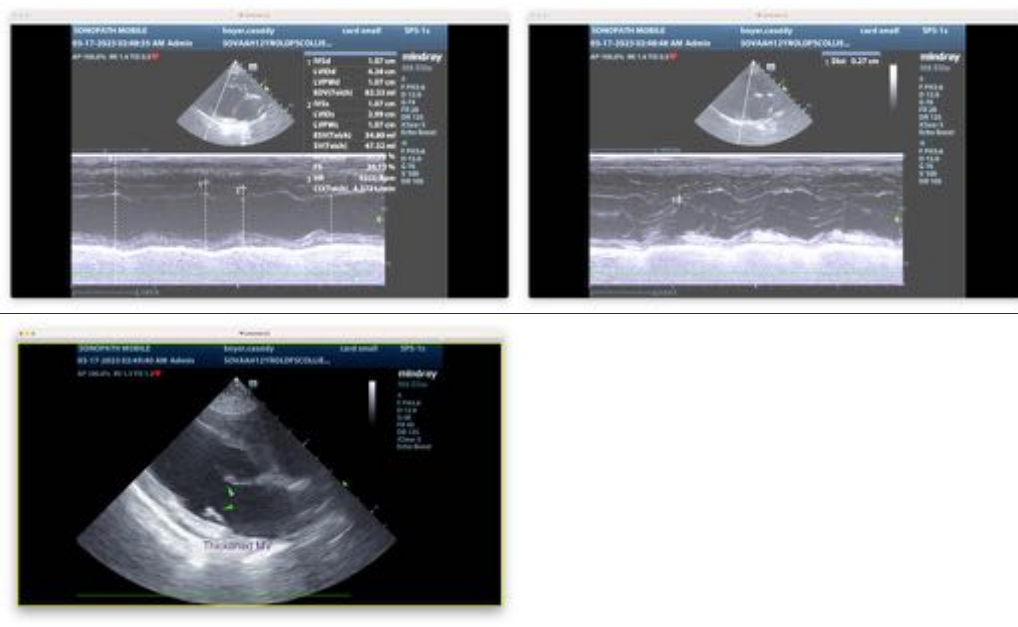
Dr. Ammeraal

INVOICE

12451

DATE

3.17.23



The information and recommendations provided are based on the images presented by the referring veterinarian/sonographer. No evaluation can be communicated regarding pathology that was not visible in the image/video clips provided.

Thank you for this referral. If the clinical or image interpretation does not parallel your findings or if I can be of any further assistance please contact me.

Tam Mengine, DVM, DABVP (canine/feline practice)

info@SonoPath.com